

PATIENT PRESENTING CLINICAL SIGNS

Cocoa Sachon

History: No clinical history noted from RDVM, recent adoption, pre anesthesia

SPECIES ECHOCARDIOGRAPHIC FINDINGS

2D, M-mode, and Doppler study.

Feline Left atrial size is normal. The mitral valve is normal. There is mild symmetrical left ventricular hypertrophy. Left ventricular internal dimensions are normal. Left ventricular systolic function is hyperdynamic. The aorta and aortic are normal. Right atrial and right ventricular dimensions are normal. The tricuspid valve is normal. The pulmonary artery and pulmonic valve are normal. No shunting lesions are visualized. No pericardial effusion or cardiac masses are seen.

BREED

DSH

SEX

Male Neutered

AGE

3 years

WEIGHT

15.9 lbs

LA/Ao - 1.43
IVSd - 6.5 mm
LVPWd - 6.2 mm
LVIDd - 14.7 mm
LVIDs - 5.6 mm
FS - 61.9%
LVOT - 1.66 m/s
RVOT - 1.01 m/s

ASSESSMENT/RECOMMENDATIONS

Hypertrophic cardiomyopathy (HCM)

INTERPRETED BY

Keith Blass, DVM,
MS, DACVIM

This examination demonstrates mild hypertrophy of Cocoa's left ventricular walls, consistent with HCM. The hemodynamic effects of the hypertrophy appear to be mild at present, as Cocoa does not have secondary dilation of his left atrium, indicating that his current risk for the development of congestive heart failure and/or thromboembolic disease appears to be low.

No therapy is recommended at this stage of disease.

IMAGING PERFORMED BY

Rebekah Jakum, CVT
ARDMS/RVT

A recheck echocardiogram is recommended in 9 months, sooner if clinical signs compatible with cardiac dysfunction develop.

HOSPITAL NAME

Rush VC

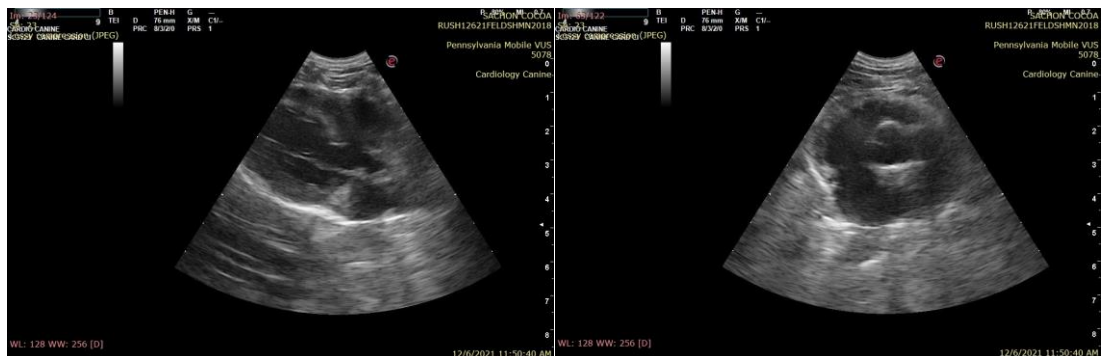REFERRING VET

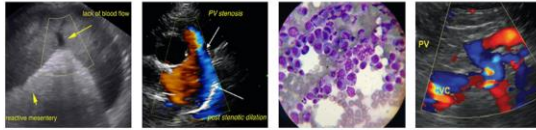
Dr. Milot

DATE

12.6.2021

The information and recommendations provided are based on the images presented by the referring veterinarian. No evaluation can be communicated regarding pathology that was not visible in the





PATIENT image/video clips provided.

Cocoa Sachon Thank you for this referral. If the clinical or image interpretation does not parallel your findings or if I can be of any further assistance please contact me.

SPECIES

Feline **Keith Blass, DVM, MS, DACVIM (Cardiology)**

KeithBlass@gmail.com

BREED

631-804-5754

DSH

SEX

Male Neutered

AGE

3 years

WEIGHT

15.9 lbs

INTERPRETED BY

Keith Blass, DVM,
MS, DACVIM

**IMAGING
PERFORMED BY**

Rebekah Jakum, CVT
ARDMS/RVT

HOSPITAL NAME

Rush VC

REFERRING VET

Dr. Milot

DATE

12.6.2021